

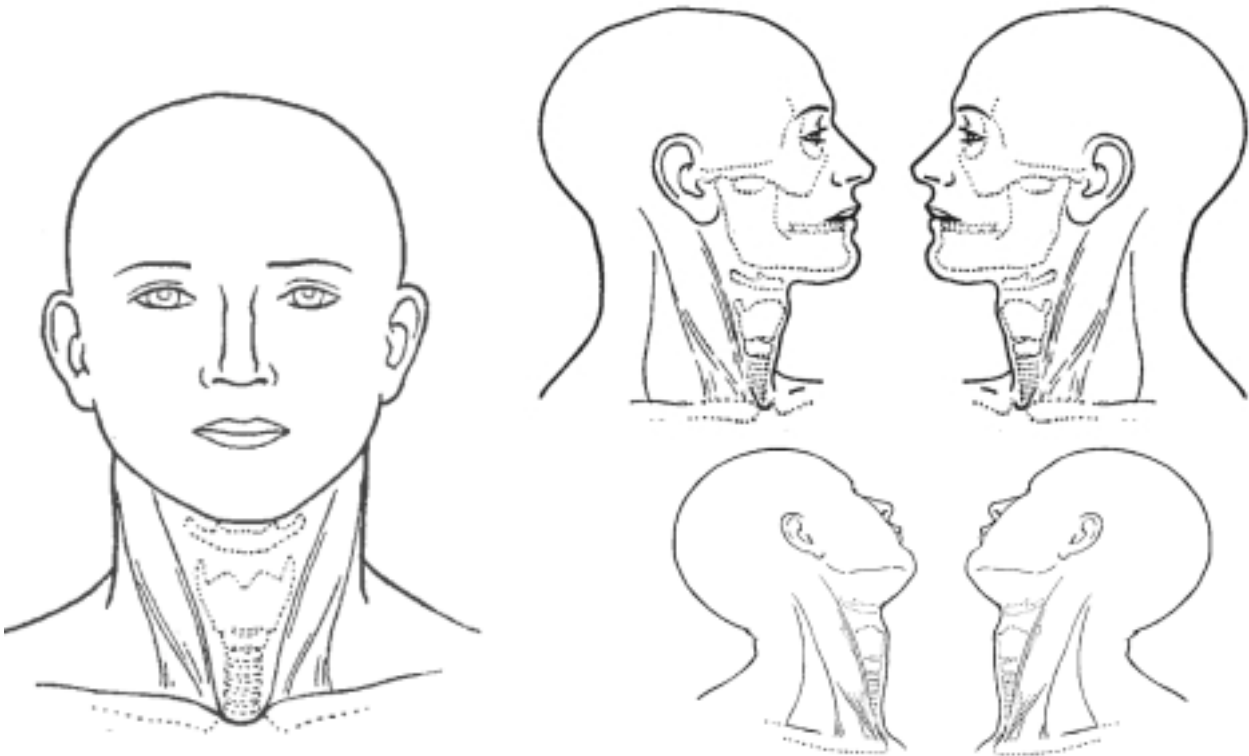
Operationsfund

Label:

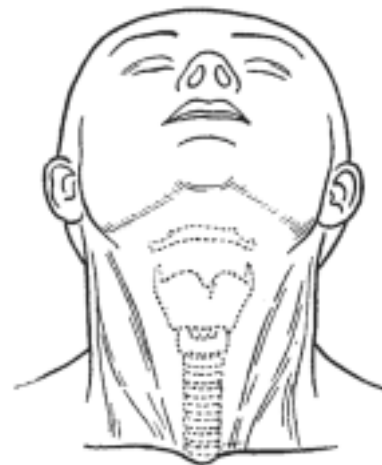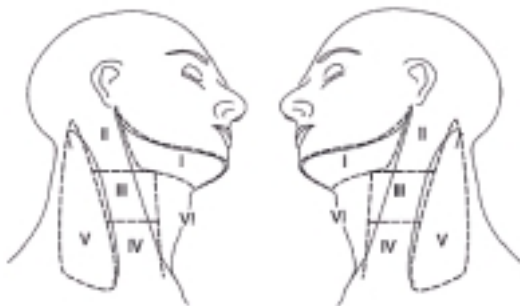Dato:

Operatør:

T-lokalisation



N-lokalisation



Kommentarer:

TNM:

Øre-næse-halsafdeling H, Århus Universitetshospital

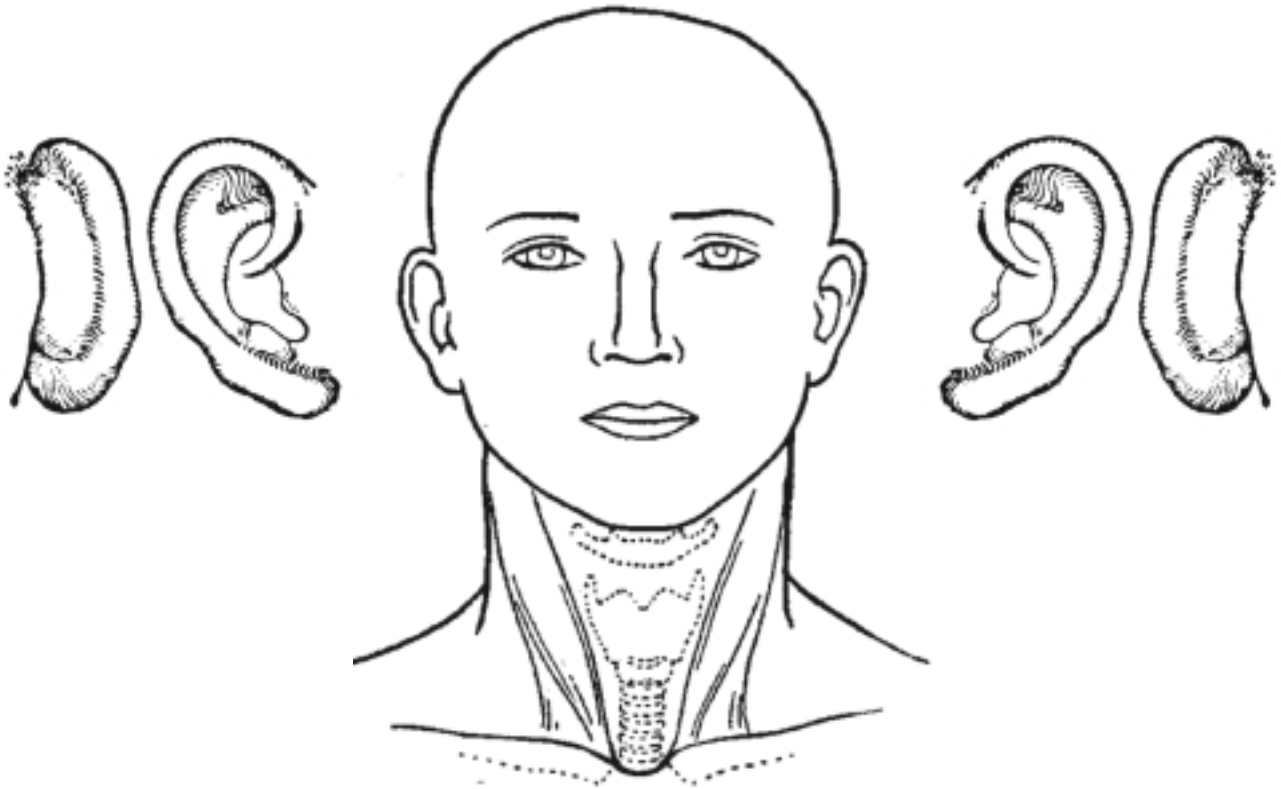
Operationsfund

Label:

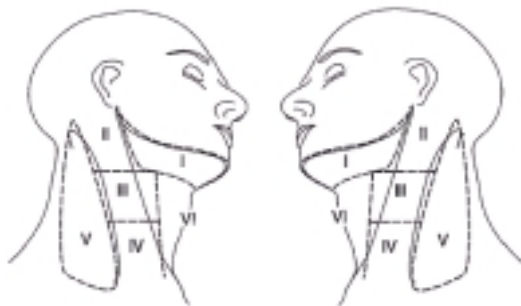Dato:

Operatør:

T-lokalisation



N-lokalisation



Kommentarer:

TNM:

Øre-næse-halsafdeling H, Århus Universitetshospital

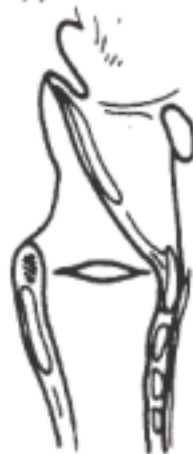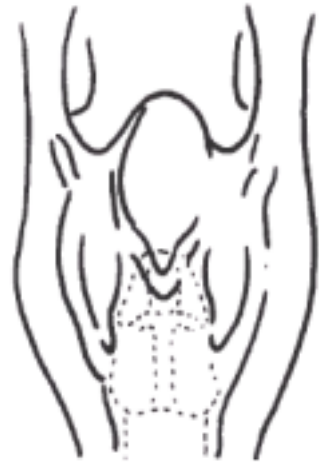
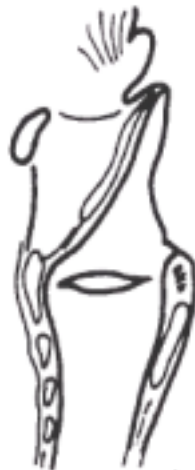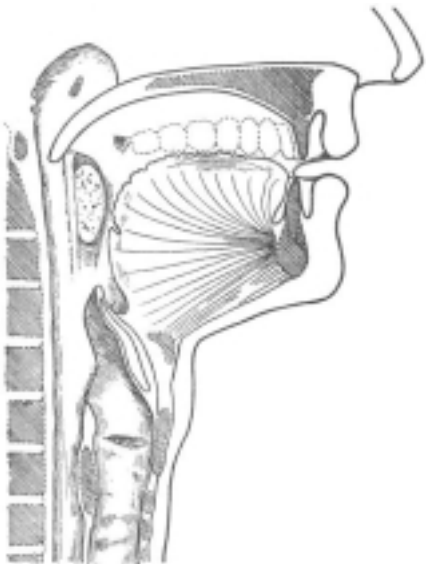
Operationsfund

Label:

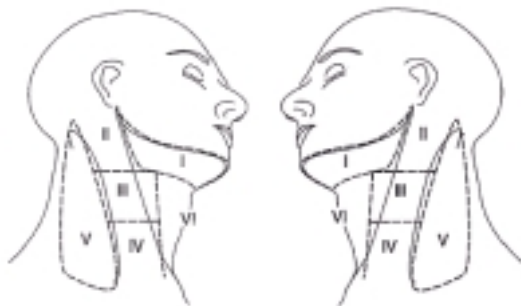Dato:

Operatør:

T-lokalisation



N-lokalisation



Kommentarer:

TNM:

Øre-næse-halsafdeling H, Århus Universitetshospital

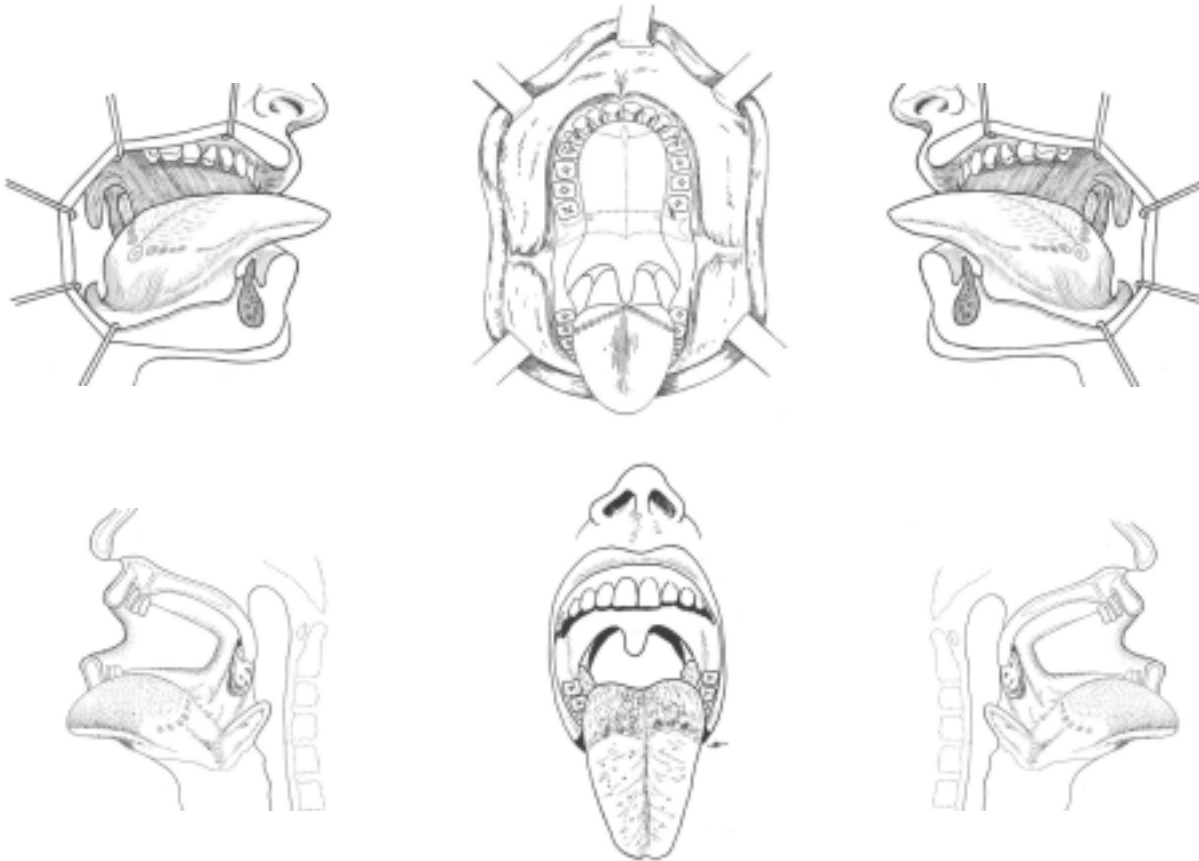
Operationsfund

Label:

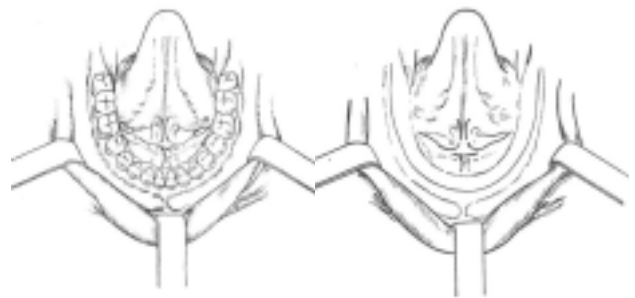
Dato:

Operatør:

T-lokalisation



N-lokalisation



Kommentarer:

TNM:

Øre-næse-halsafdeling H, Århus Universitetshospital

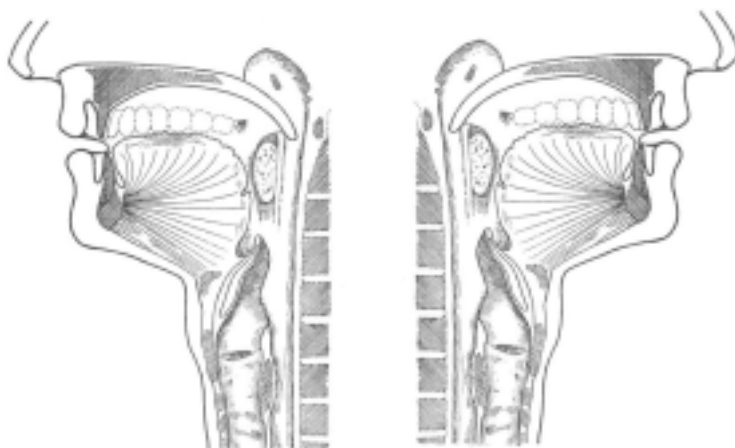
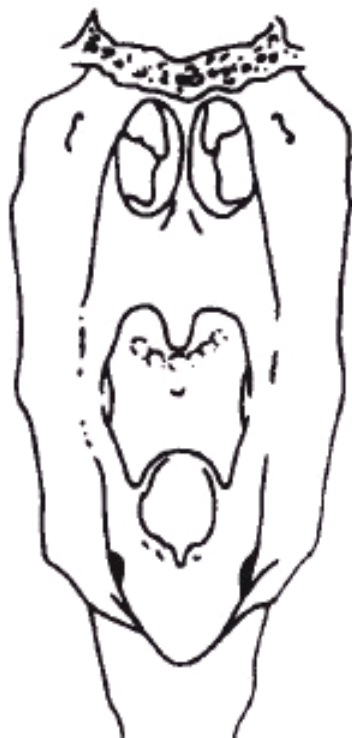
Operationsfund

Label:

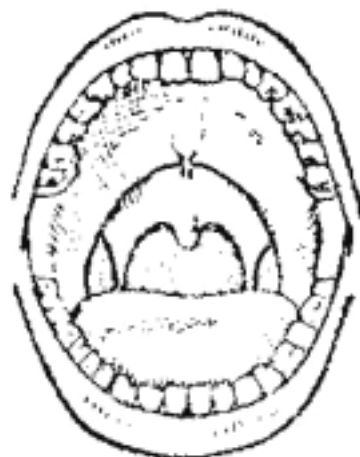
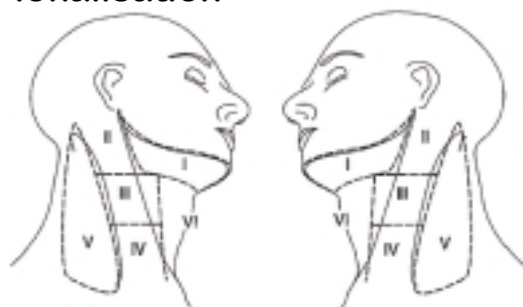Dato:

Operatør:

T-lokalisation



N-lokalisation



Kommentarer:

TNM:

Øre-næse-halsafdeling H, Århus Universitetshospital

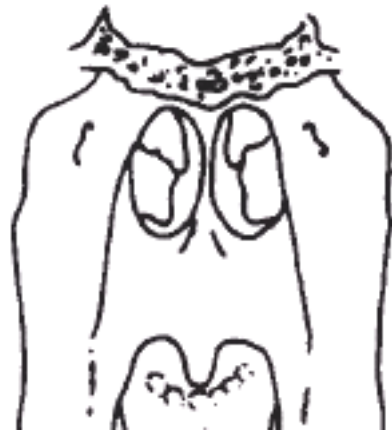
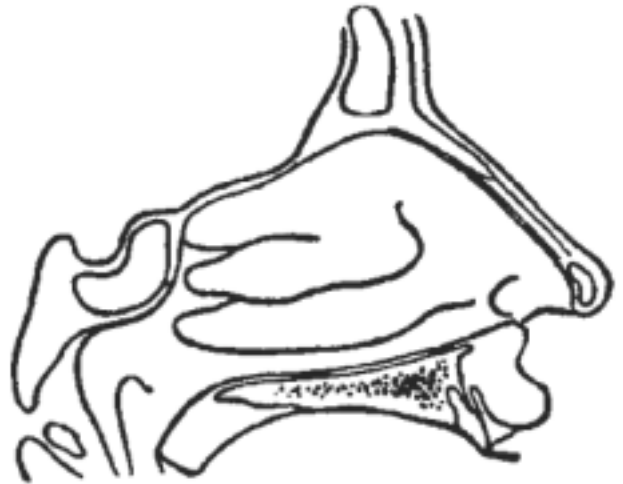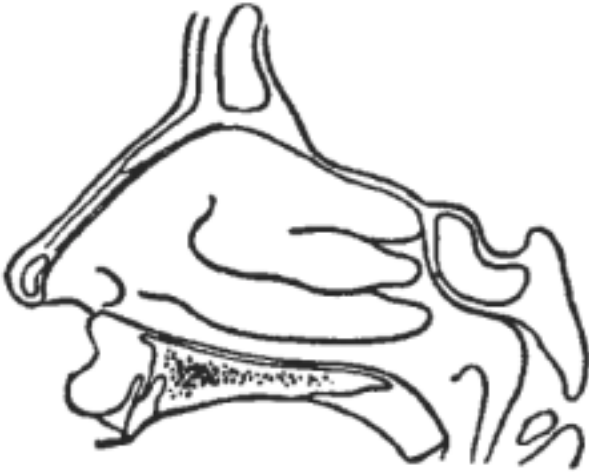Operationsfund

Label:

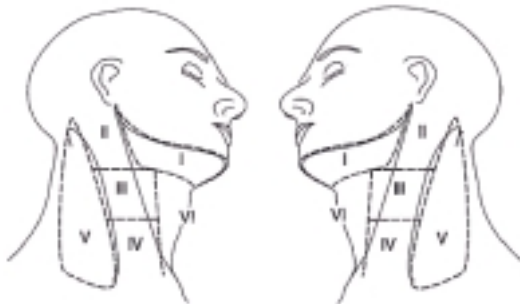Dato:

Operatør:

T-lokalisation



N-lokalisation



Kommentarer:

TNM:

Øre-næse-halsafdeling H, Århus Universitetshospital